



# Gastric outlet obstruction & Carcinoma of Stomach

**Dr. Muhammad Shamim**

*FCPS (Pak), FACS (USA), FICS (USA), MHPE (NI & Eg)*

*Assistant Professor, Dept. of Surgery*

*College of Medicine, Prince Sattam bin Abdulaziz University*

*Email: [surgeon.shamim@gmail.com](mailto:surgeon.shamim@gmail.com)*

*Web: [surgeonshamim.com](http://surgeonshamim.com)*

# Gastric outlet obstruction

# Etiology

1. Gastric carcinoma.
2. Pyloric stenosis secondary to peptic ulcer (stenosis of 1<sup>st</sup> part of duodenum).
3. Adult pyloric stenosis (pyloric channel stenosis).
4. Pyloric mucosal diaphragm.

# Clinical features

- In pyloric stenosis there is usually a long history of peptic ulcer disease, with loss of periodicity.

## *Symptoms*

- Epigastric pain & fullness, more towards evening.
- Vomiting:
  - Very large, foul & frothy vomits (totally lacking in bile)
  - once a day, in evening;
  - often consist of foodstuff taken several days before.
  - gives considerable relief.

## *Signs*

- In thin pts, gastric outline can be seen.
- Visible peristaltic waves passing from left to right.
- succussion splash.
- Tetany (due to alkalosis).
- Loss of weight.
- Dehydration.

## *Metabolic effects*

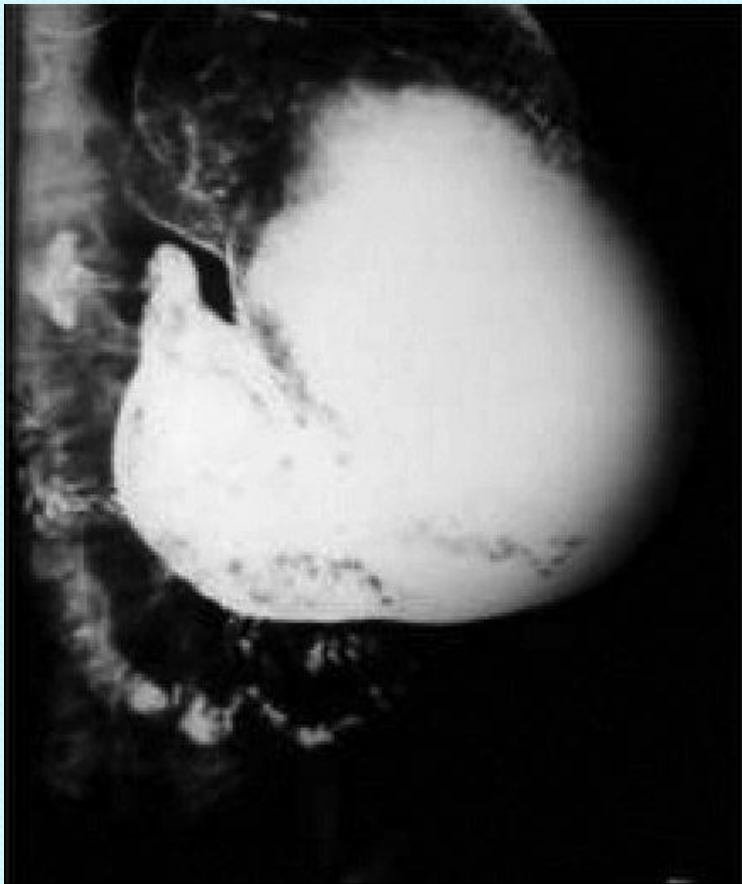
These occur in benign pyloric stenosis;

- Vomiting of HCl results in **hypochloremic alkalosis**.
- Initially the Na & K ions levels may be normal, & the urine has a low Cl & high HCO<sub>3</sub> content. This HCO<sub>3</sub> is excreted along with Na, & so with time the patient becomes progressively **hyponatremic** & more **dehydrated**.
- Because of dehydration, **Na retention** follows, & K & H ions are excreted in preference. This results in the urine becoming paradoxically acidic & **hypokalemia** occur.
- Alkalosis leads to **hypocalcemia**, & **tetany** can occur.

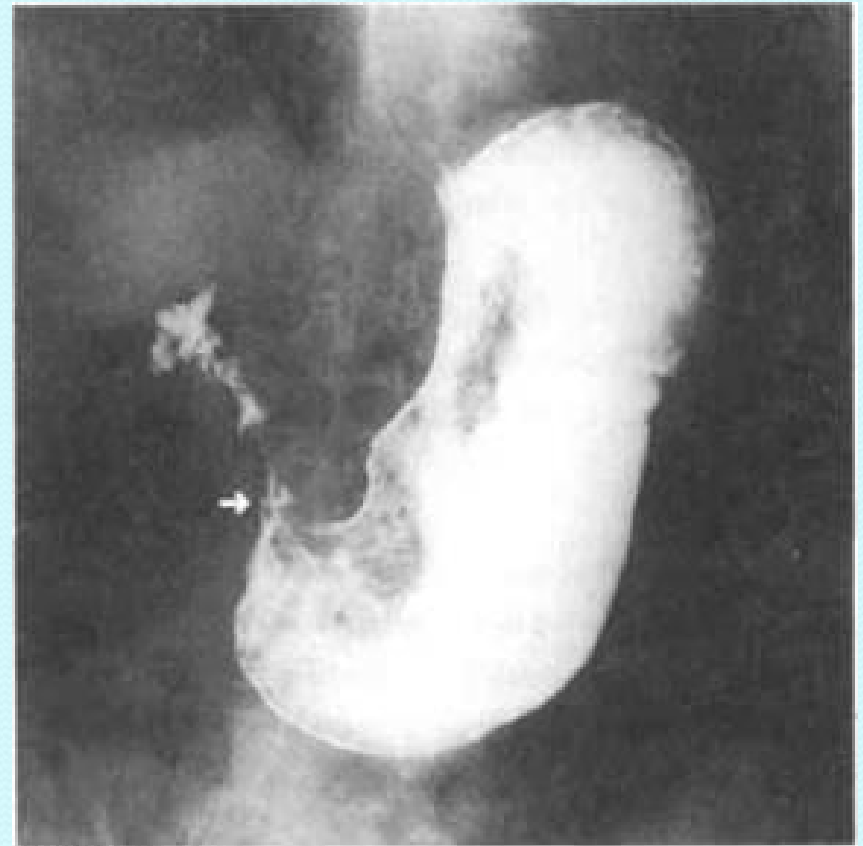# Diagnostic Investigation

- ***X-ray with barium meal***
  - Stomach is large & low, it is never empty, & barium is mixed with food residue.
  - There is much delay in its evacuation.
- **CT scan**
  - may reveal gastric distention along with retained material within the gastric lumen.
  - often also suggest the specific cause of GOO.
- ***Endoscopy***
  - Biopsy of the area around the pylorus is essential to exclude malignancy.

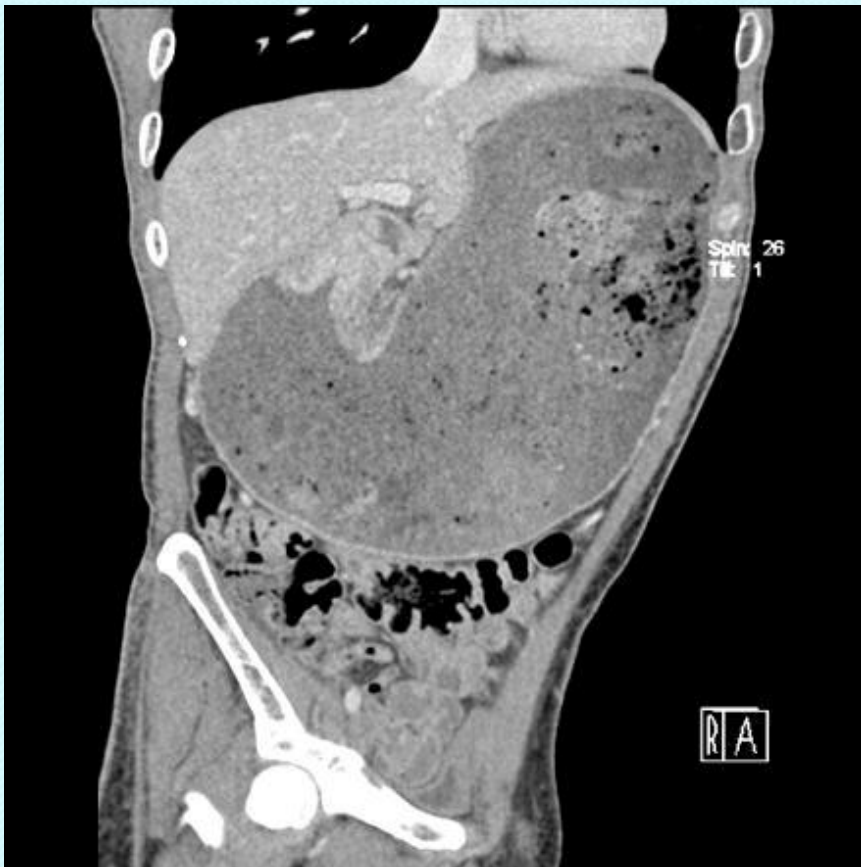The point of obstruction is at the pyloric-duodenal junction (string sign).



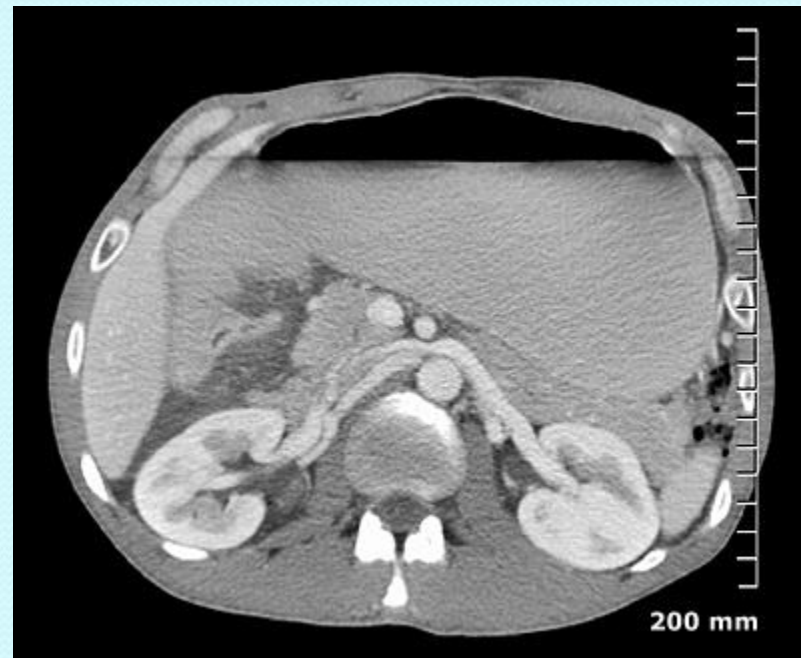GOO due to carcinoma of the pyloric antral region (arrow).



## GOO due to adenocarcinoma

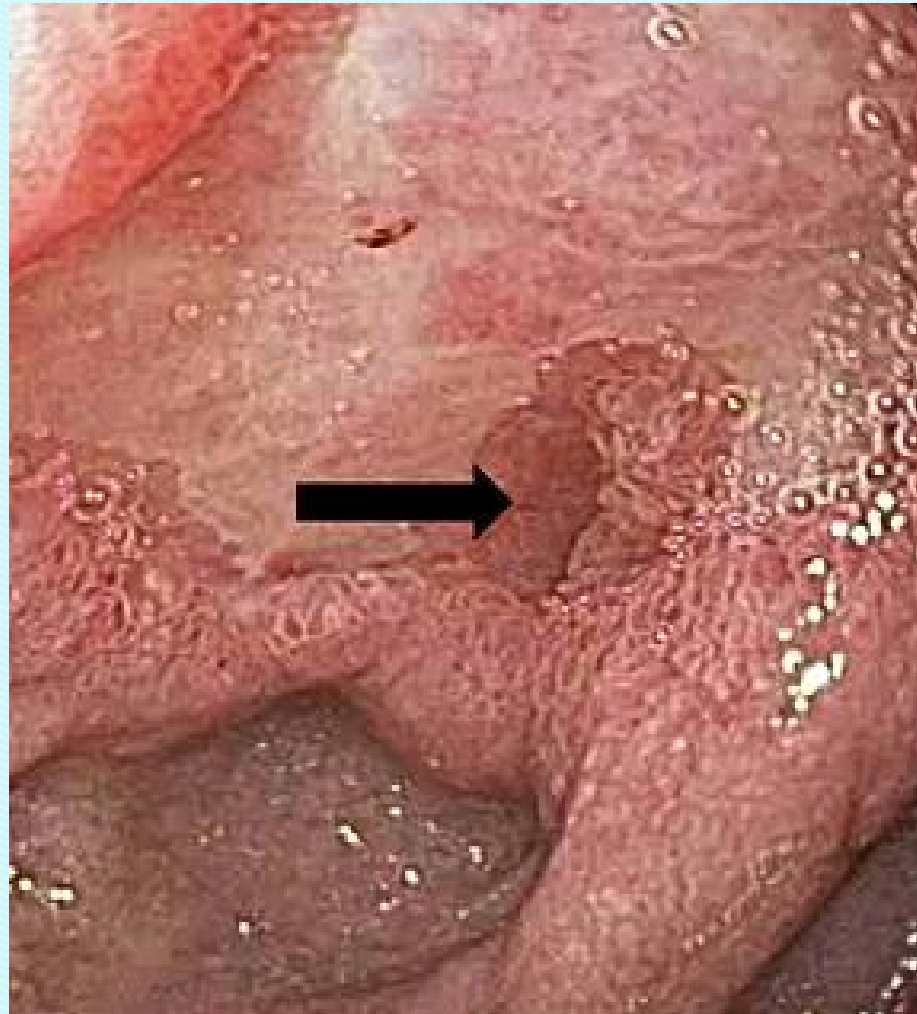

## GOO due to peptic ulcer disease showing a distended and fluid filled stomach





- Endoscopic view of the pre-pylorus in chronic peptic ulcer disease.



# Treatment

- ***Preliminary treatment***
  - Gastric lavage with saline thru a wide-bore tube for 4-5 days.
  - A high protein fluid diet.
  - Correction of metabolic abnormalities.
    - intravenous isotonic saline with potassium supplement.
    - Replacing the NaCl & water allows the kidney to correct the acid-base abnormality.
- ***Medical treatment***
  - PPIs or H<sub>2</sub>-blockers.
  - Endoscopic balloon dilatation.
- ***Operation***
  - For benign disease, drainage procedure performed,
    - eg truncal vagotomy & gastrojejunostomy or Billroth II gastrectomy.
  - For malignant disease, appropriate resectional surgery is performed.

# Carcinoma of Stomach

- Described as one of the ‘Captains of the men’s death’.
- Overall 5-year survival is 5 %.
- It is a curable disease provided that it is detected at an appropriate stage and treated adequately.
- Early diagnosis is therefore the key to success.

# Incidence

- UK: 15 per 100 000 per year
- USA: 10 per 100 000 per year
- Japan: 70 per 100 000 per year

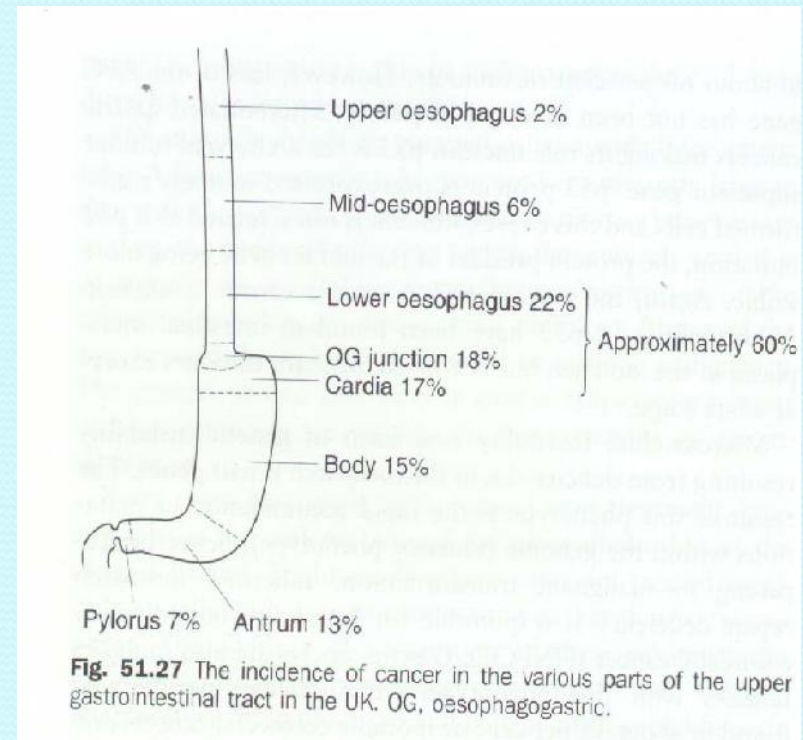
# Etiology

- **Helicobacter pylori** (gastritis, gastric atrophy and intestinal metaplasia).
- Pernicious anemia & gastric atrophy.
- Gastric polyp.
- **Peptic ulcer surgery** eg, Billroth II or Polya gastrectomy, gastroenterostomy, pyloroplasty or vagotomy.
  - duodenogastric reflux and reflux gastritis
- Autoimmune & environmental gastritis.
- Intestinal metaplasia.
- **Cigarette smoking.**
- Excessive salt intake.
- Deficiency of antioxidants.
- Exposure to N-nitroso compounds.
- Genetic factors.

# Pathology

## Site

- Pylorus → 10 %
- Antrum → 18.57 %
- Body → 21.43 %
- Cardia → 24.29 %
- Esophagogastric junction → 25.71 %



## ***Macroscopic types***

- ***Lauren classification***

- **Intestinal gastric cancer:**

- It resembles a carcinoma elsewhere in tubular GIT, & forms polypoid tumors or ulcers.
- It probably arises in areas of intestinal metaplasia.

- **Diffuse gastric cancer:**

- It infiltrates deeply into the stomach wall without forming obvious mass lesions.

- **Mixed morphology.**



## ***Microscopic type***

**Growth is usually columnar-celled, but cubical, & even squamous-celled neoplasms arise near esophageal orifice.**

### **Early gastric cancer**

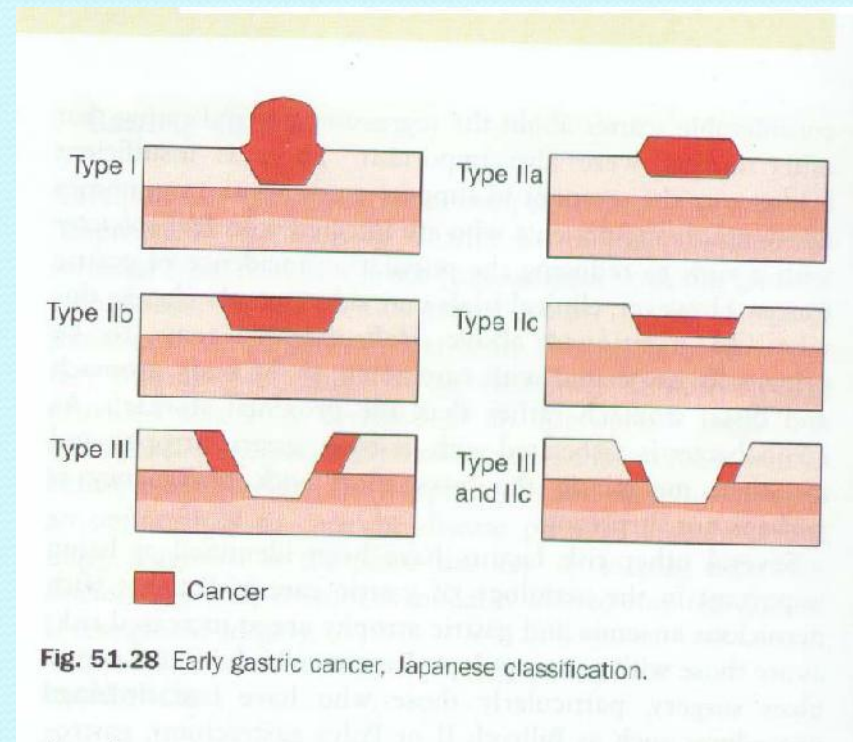
- **Limited to mucosa & submucosa, irrespective of lymph node metastases (T1, any N).**

### **Advanced gastric cancer**

- **Infiltrates the muscularis, & perhaps spread more widely.**

## *Japanese classification*

- **Type I:** Protruded type (> 0.5 cm height).
- **Type II:** Superficial type (< 0.5 cm height).
  - **Type IIa:** Slightly elevated surface.
  - **Type IIb:** Flat surface.
  - **Type IIc:** Slightly depressed surface.
- **Type III:** Excavated.



## *Bormann's classification*

- **Type I:** Broad-based elevated polypoid lesion.
- **Type II:** Elevated lesion with ulceration & well-demarcated margin.
- **Type III:** Elevated lesion with ulceration & ill-defined margin.
- **Type IV:** Ill-defined flat lesion (**linea plastica**).

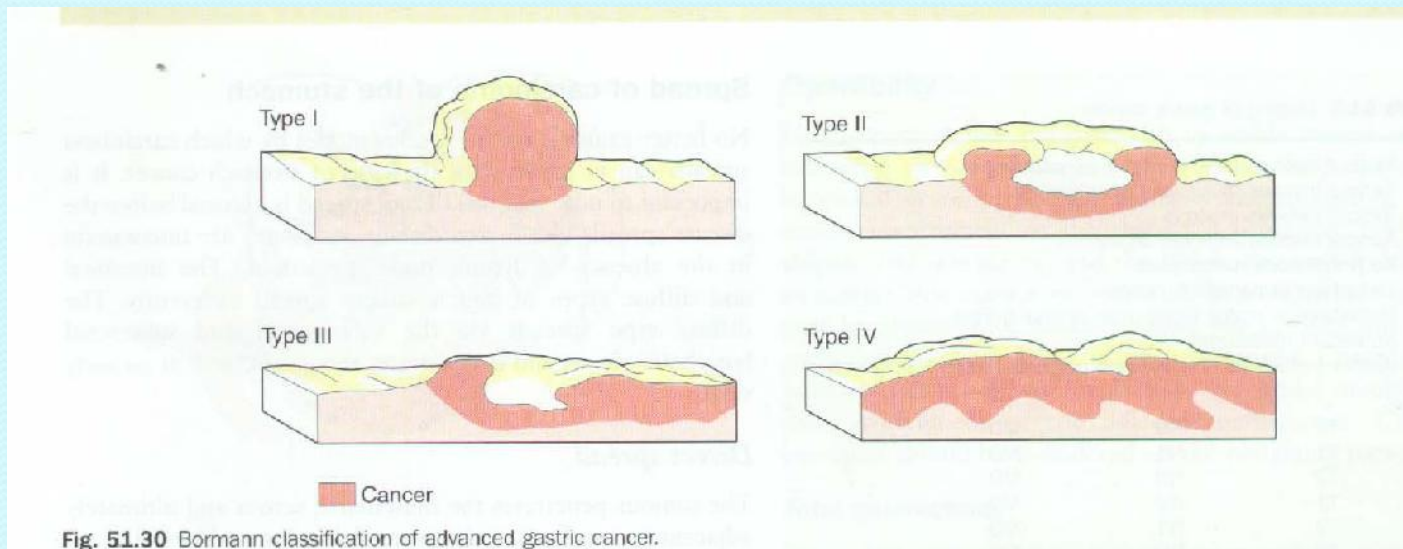


Fig. 51.30 Bormann classification of advanced gastric cancer.

## **Spread**

- **Direct spread** to Pancreas, transverse colon, transverse mesocolon, esophagus, or liver.
- **Lymphatic spread** may be extensive, tumor even appearing in left supraclavicular nodes (**Virchow's nodes, Troisier's sign**).
- **Spread by bloodstream** to liver, lungs & bone.
- **Transperitoneal spread**
  - Advance disease may be palpated either abdominally or rectally as a tumor shelf, referred as **Blumer shelf**.
  - It can spread anywhere in the peritoneal cavity eg ovaries (**Krukenberg's tumors**), or via the peritoneal cavity to the umbilicus (**Sister Joseph's nodule**).

# Staging

## Classification of International Union Against Cancer (UICC);

- **T1** □ Tumor involves lamina propria or submucosa.
- **T2** □ Tumor involves muscularis or subserosa.
- **T3** □ Tumor involves serosa.
- **T4** □ Tumor invades adjacent organs.
- **N0** □ No lymph node metastases.
- **N1** □ Metastasis in 1-6 regional nodes (within 3 cm of primary).
- **N2** □ Metastasis in 7-15 regional nodes (> 3 cm of primary).
- **N3** □ Metastasis in more than 15 regional nodes.
- **M0** □ No distant metastasis.
- **M1** □ Distant metastasis (includes peritoneum & distant nodes).

# Clinical Features

## Symptoms

- Vague but **persistent indigestion or epigastric pain**;
  - no response to treatment & no periodicity (esp. if it occur for the first time after 40 years).
- **Anorexia**, & weight loss.
- Tiredness, & weakness.
- **Gastric distension** & vomiting (ca of pylorus).
- **Dysphagia** (carcinoma of cardia).
- Lump in epigastrium.

# Signs

- **Wasting.**
- Pallor or **anemia** (due to chronic bleeding from carcinoma or lack of protein & iron in diet).
- **Jaundice** (due to secondary deposits in liver).
- **Troisier's sign:** A visible as well as a palpable mass of lymph nodes in left supraclavicular fossa (Virchow's node).
- Abdomen may be **scaphoid** with wrinkled & inelastic skin, or distended from **ascites** (due to peritoneal carcinomatosis).
- Epigastric tenderness.
- Epigastric mass.
- **Succussion splash**, if pyloric obstruction is present.
- **Trousseau's sign:** Phlebothrombosis of superficial veins of legs.
- Krukenberg's tumor.

# Investigations

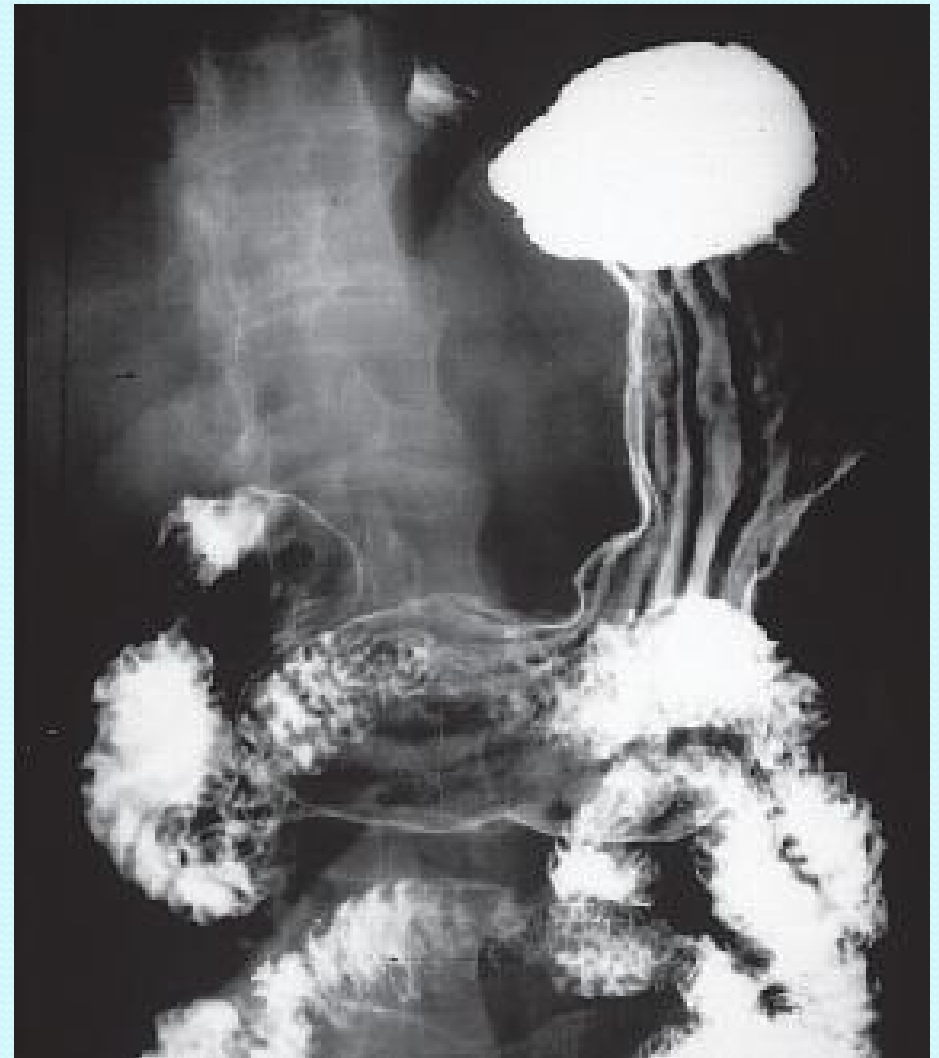- ***Hemoglobin estimation***
  - Reveal anemia in 45% of cases.
- ***Test for occult blood in stool***
- ***Exfoliative cytology***
- ***Radiology with double contrast barium meal***
  - For cardiac & fundus growth, examination in inverted position is required.
  - Macroscopic types may be recognized, but flat growths may remain undetected in early stages.
- ***Gastroscopy***
  - Nodularity, irregular ulcers, multicolored base, immotility of adjacent mucosa, all points towards malignancy.
  - Multiple biopsies are taken.
  - ***Histologic examination of biopsy*** reveal microscopic types & extent of growth.



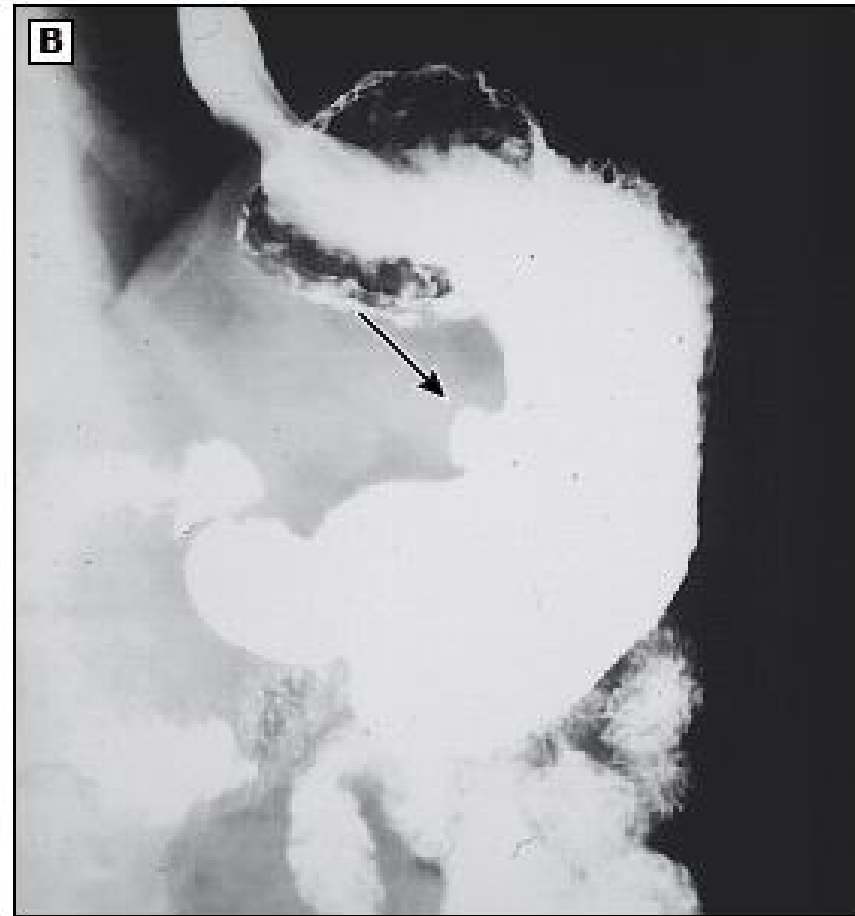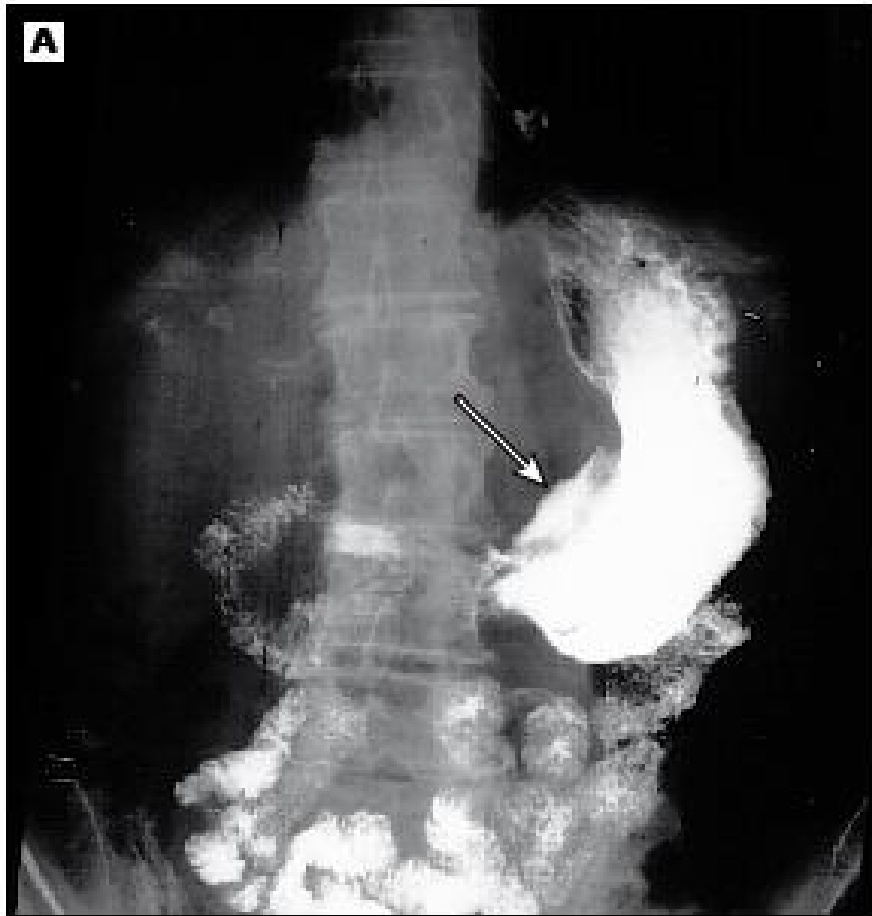
# Staging investigations

- **Abdominopelvic CT scan**
  - best suited to evaluate metastatic disease, esp hepatic or adnexal metastases, ascites, or distant nodal spread.
- **Endoscopic ultrasonography**
  - most reliable nonsurgical method for evaluating the depth of invasion of primary gastric cancers, esp early (T<sub>1</sub>) lesions.
  - Its accuracy for T<sub>1</sub> to T<sub>4</sub> ranges from 77 to 93 percent.
- **PET scan**
  - integrated PET/CT imaging can be useful to confirm malignant involvement of CT-detected lymphadenopathy.
  - it is more sensitive than CT for the detection of distant metastases.
- **Chest imaging**
  - for detection of metastases chest CT scan is preferred
- **Serologic markers**
  - Serum levels of CEA, glycoprotein CA 125 antigen (CA 125), CA 19 9, and CA 72 4 may be elevated
- **Laparoscopy**
  - more invasive than CT or EUS,
  - has the advantage of directly visualizing the liver surface, the peritoneum, and local lymph nodes.

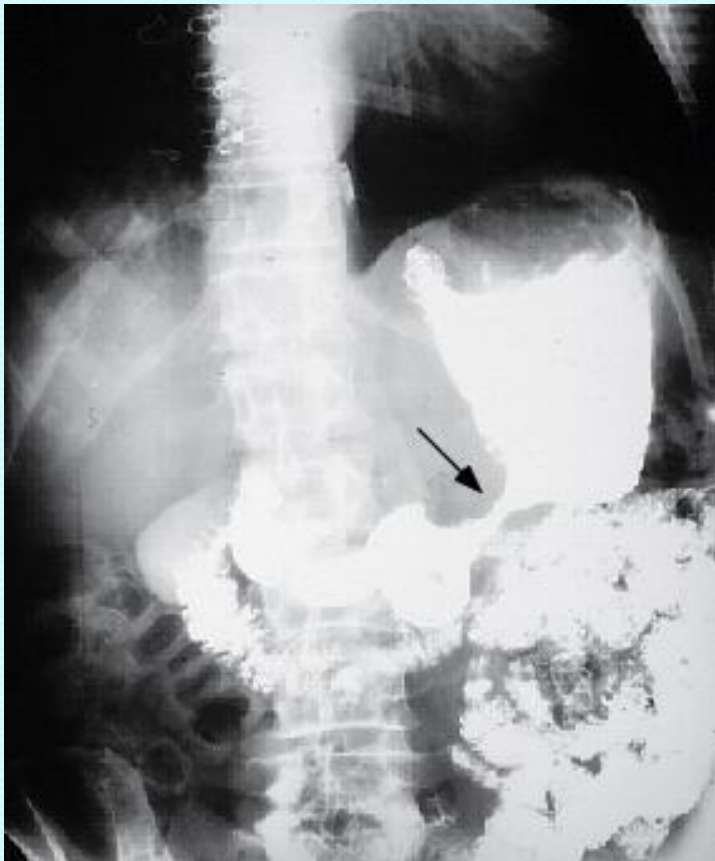- Normal air-contrast upper gastrointestinal study showing normal gastric folds and small intestinal anatomy.



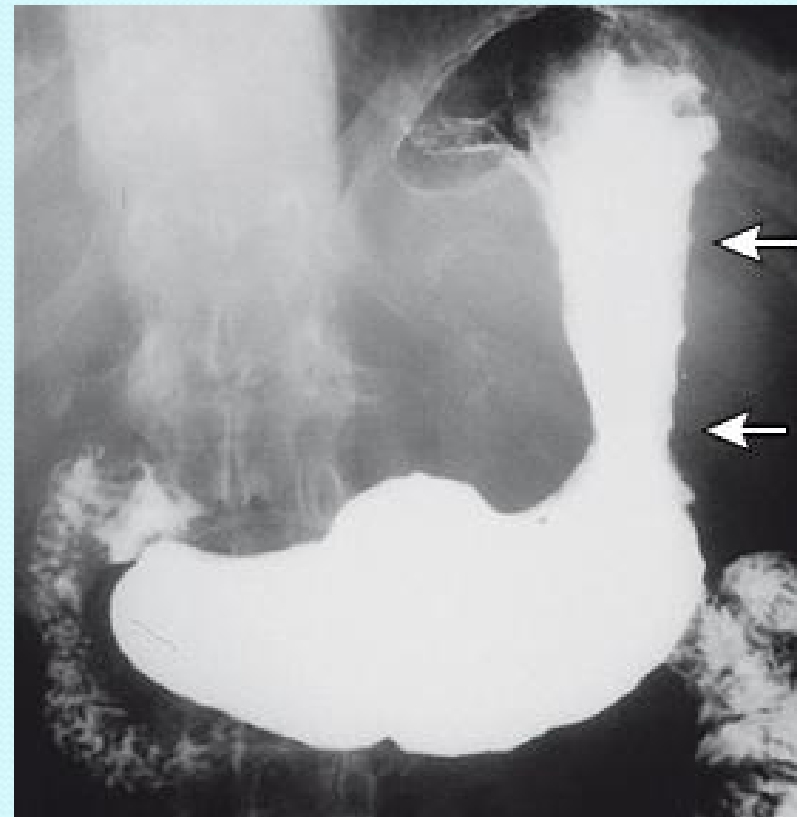
- (A) **Malignant gastric ulcer** of the distal lesser curvature. There is the biconvex meniscus sign with a nodular ulcer mound (arrow).
- (B) **Benign gastric ulcer** of the lesser curvature. The ulcer crater has smooth margins and projects beyond the gastric wall (arrow).



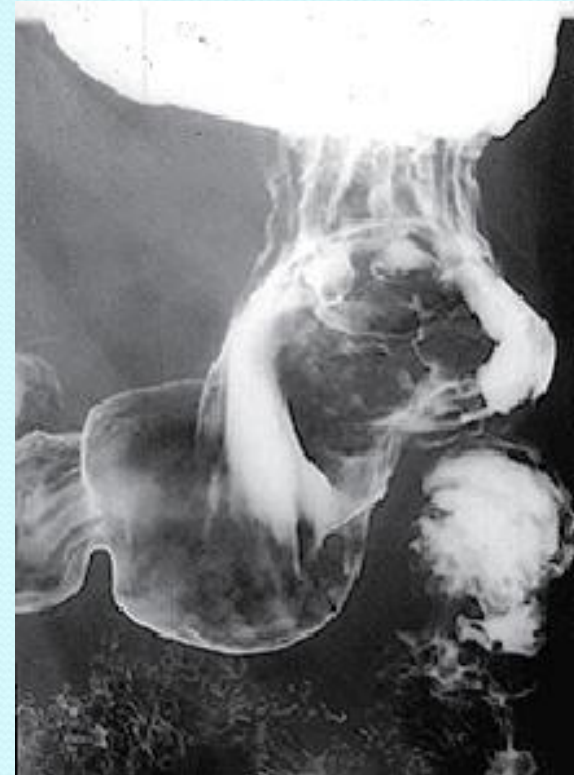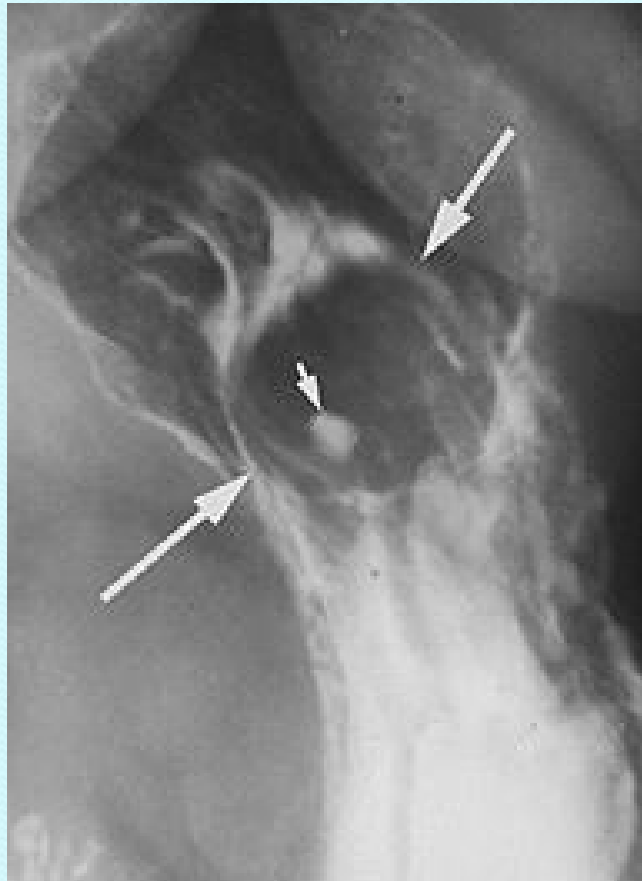
- Upper GI series showing infiltrating gastric carcinoma in the region of the incisura. There is irregular narrowing affecting both the lesser and greater curvatures (arrow).



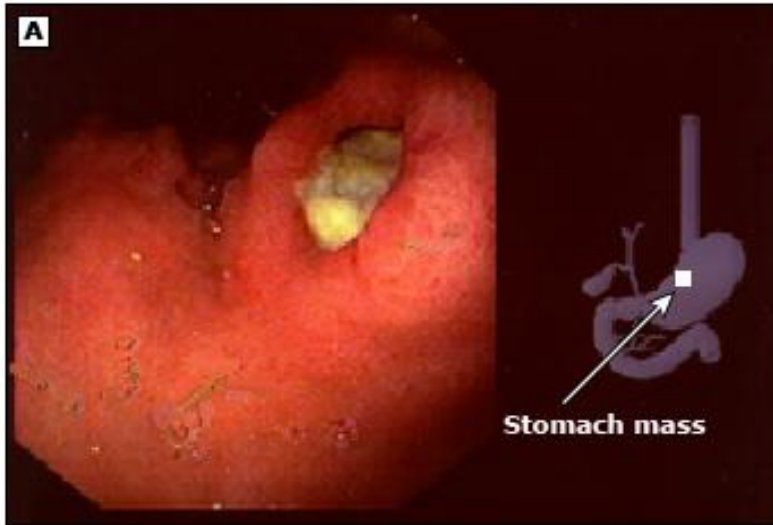- Upper gastrointestinal study reveals fixed narrowing of the entire proximal stomach (arrows) due to submucosal invasion by a gastric cancer.



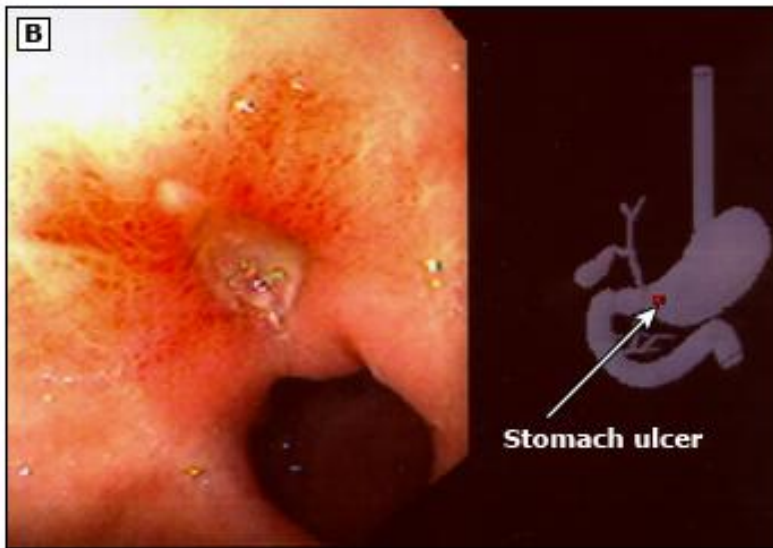
- Showing (below) a well circumscribed smooth-appearing mass (large arrows) arising from the wall of the proximal lesser curvature. A small central ulcer crater filled with barium (small arrow) along with the well- defined margins of the mass are typically seen with leiomyomas.



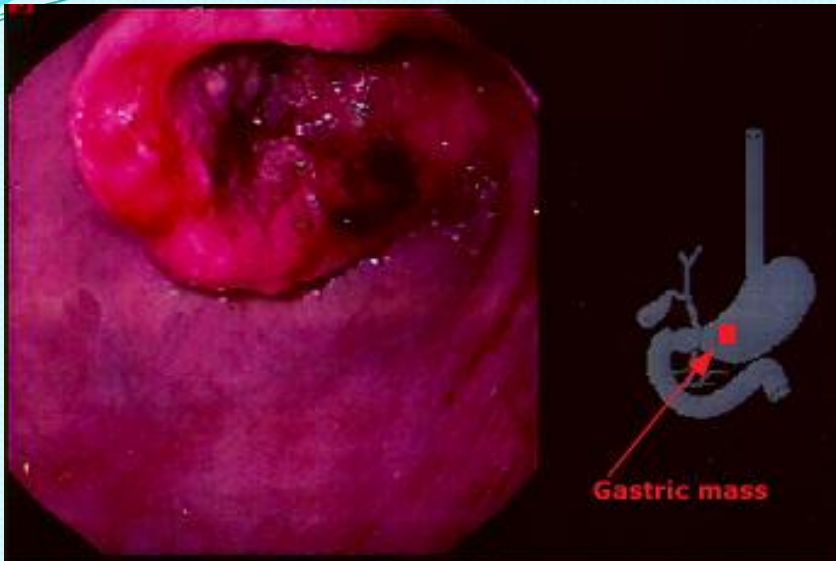- Double contrast study shows a large irregular polypoid mass arising from the greater curvature of the stomach.



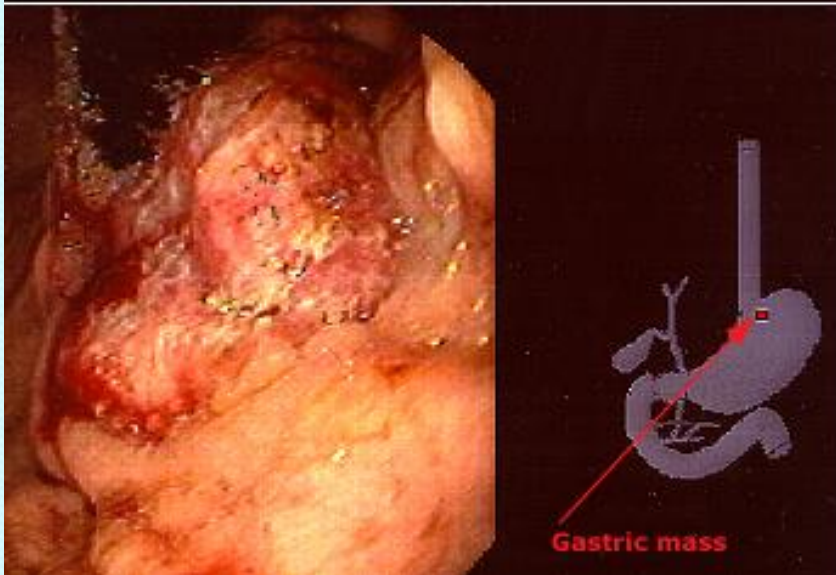
(A) Malignant gastric ulcer of the cardia. Note the absence of folds radiating to the base and the exophytic appearance.



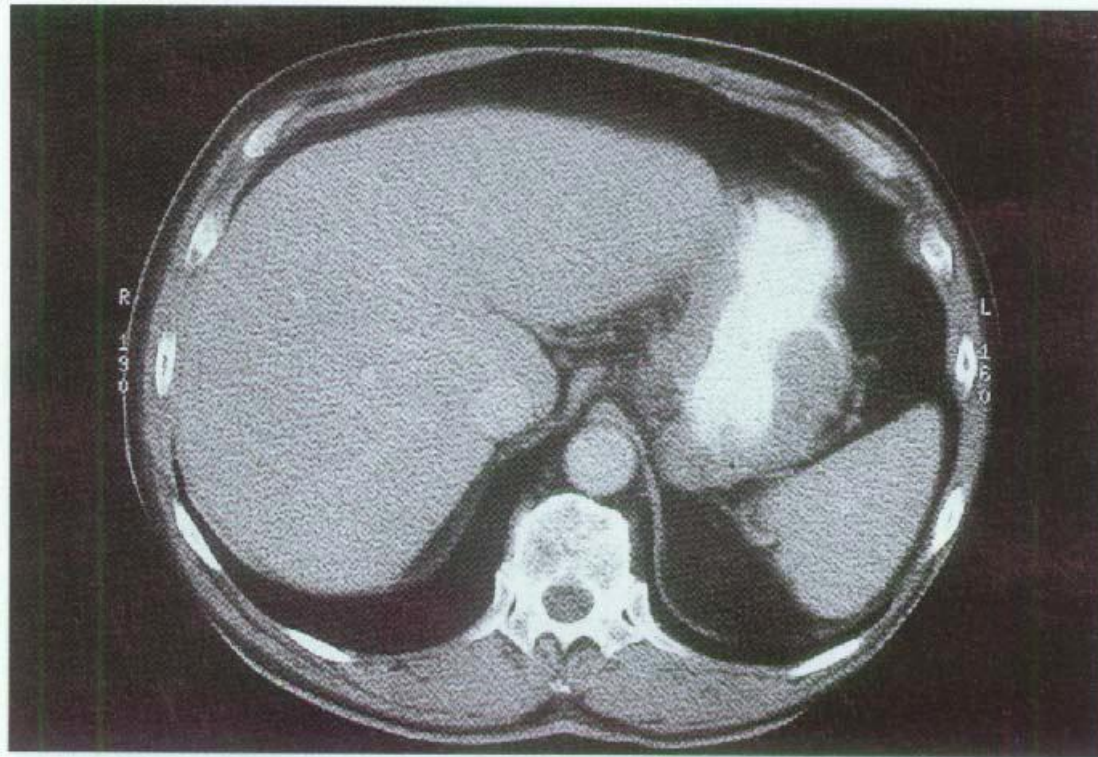
(B) Benign gastric ulcer in the prepyloric region. The ulcer is well-circumscribed with folds radiating to the ulcer base.



- Adenocarcinoma in the antrum manifested by a friable, ulcerated, and circumferential mass.

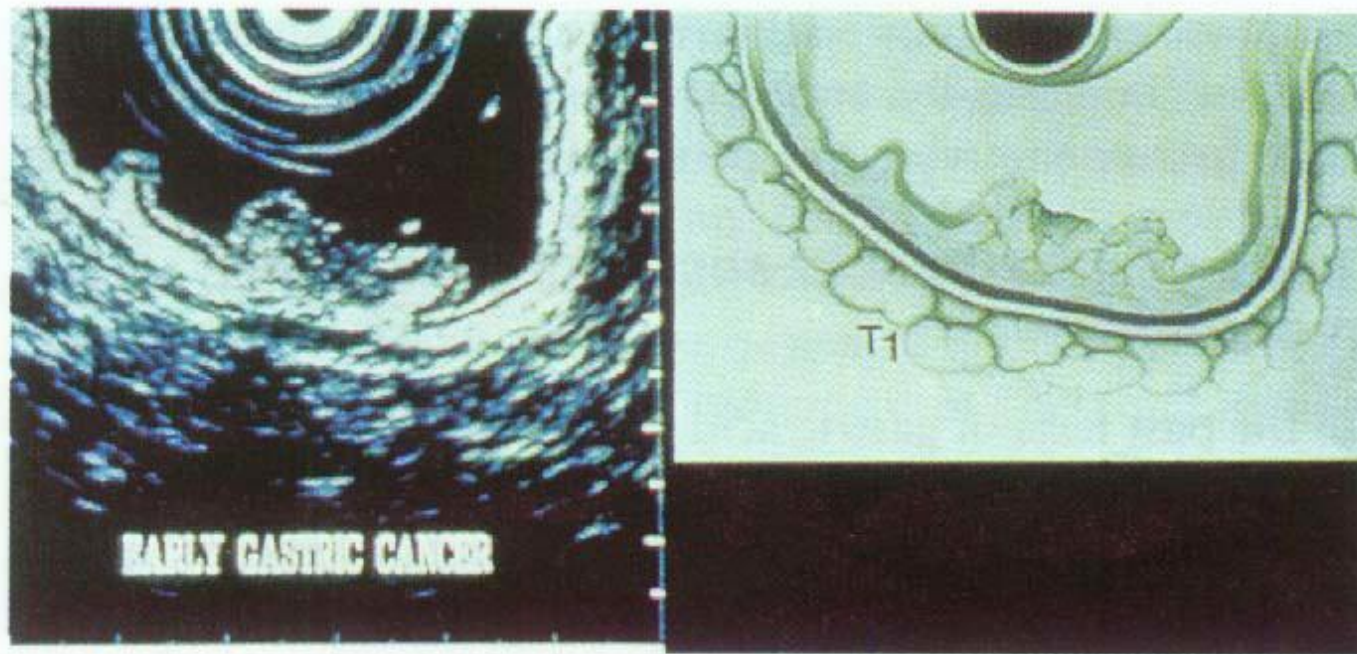


- Adenocarcinoma of the cardia. This large, lobulated, ulcerated mass was seen only by retroflexed views.

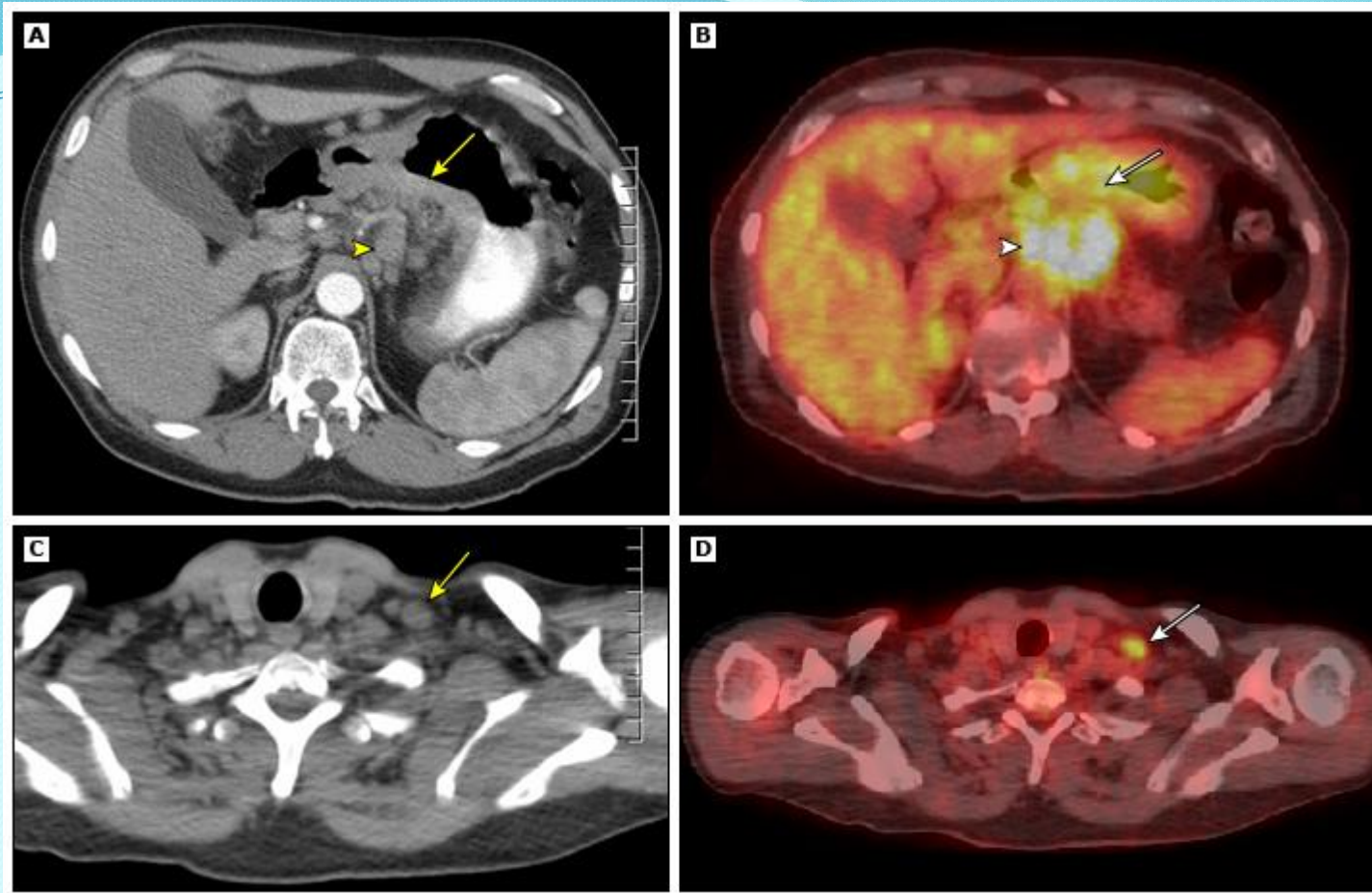


**Fig. 51.8** A CT scan of the abdomen showing a gastric cancer arising in the body of the stomach.





**Fig. 51.7** Endoscopic ultrasound of the stomach. Five layers can be identified in the normal stomach. A gastic cancer is shown invading the muscle of the gastric wall (courtesy of KeyMed (Medical and Industrial Equipment) Ltd).



- An axial CT shows gastric wall thickening (arrow) and a group of large lymph nodes in the gastrohepatic ligament (arrowhead).
- Image B is a PET CT and shows a hypermetabolic mass in the stomach (arrow) and metastatic lymph nodes in the gastrohepatic ligament.
- Image C is an axial CT image through the thoracic inlet and shows a large lymph node in the supraclavicular region (arrow).
- Image D is a PET CT showing hypermetabolic activity in the supraclavicular node indicating metastatic disease.

# TREATMENT

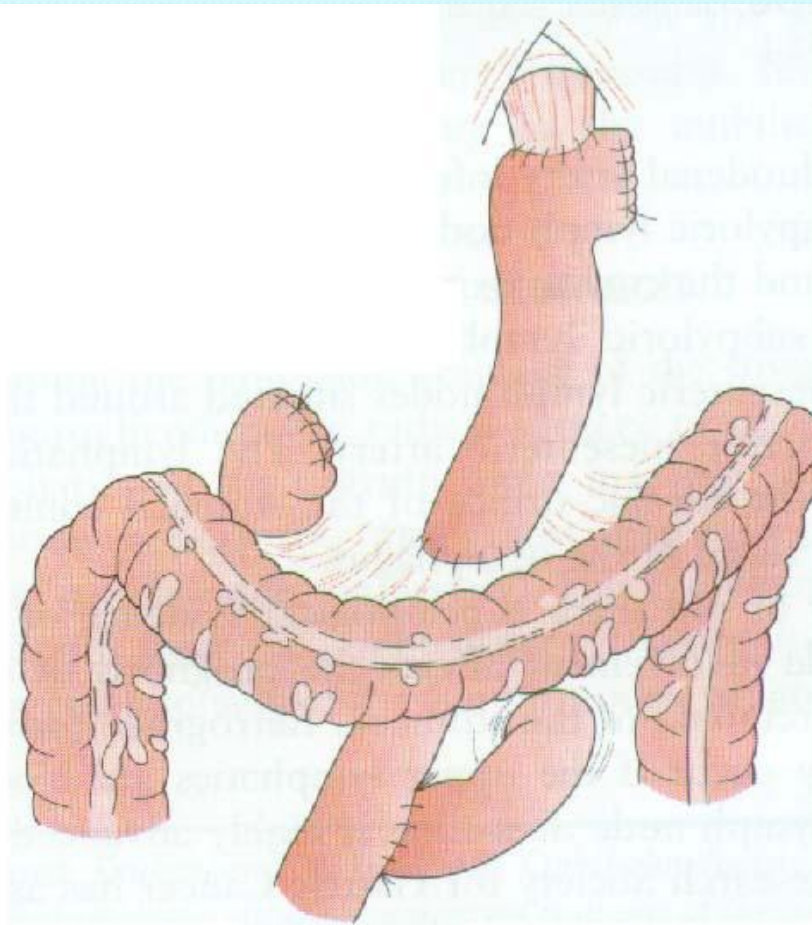
# Operation

- ***Incision***
  - Abdominal approach, thru right upper paramedian incision.
  - Abdomino-thoracic approach, if gastroesophageal junction is involved.
- ***Look for signs of inoperability***
  - Fixation to pancreas or posterior abdominal wall or involvement of mesentery esp. the origin of superior mesenteric vessels.
  - Gross local involvements of lymph nodes leading to fixity, & evidence of retrograde spread downwards in preaortic lymph nodes.
  - Presence of secondaries in liver.
  - Peritoneal seedlings either locally or in pelvis.
- ***3 possibilities***
  - Radical surgery.
  - Palliative surgery.
  - Lesion may be inoperable.

# Radical operations

## Total gastrectomy

- Indicated for **growth involving upper or middle 2/3 of stomach.**
- **Spleen is preserved**, but its hilar lymph nodes, stomach, & splenic vessels, are mobilized from left to right en bloc.
  - Left gastric artery is ligated.
  - **Lymph nodes around celiac axis & cardiac orifice** are freed, & **lesser omentum** is detached as far from stomach as possible.
  - Similarly, **subpyloric lymph nodes** are mobilized & **greater omentum** is detached from transverse colon.
- **First part of the duodenum** is divided.
- Continuity is reconstituted by means of a **Roux loop (esophagojejunostomy, end to side or end to end)**, placed in either anticollic or retrocolic position.
  - End to side jejunojunostomy is then fashioned.
- **Postoperative care** of total gastrectomy
  - Here nutritional disorders, eg, weight loss & steatorrhea (early), & macrocytic anemia (5-6 years) appear. So, these patients need:
    - Frequent small meals of high protein & high calorie content.
    - Regular vit. B<sub>12</sub> supplements (100-200 mg monthly).



**Fig. 51.34** Oesophagojejunostomy Roux-en-Y. [Reproduced with permission from *Rob and Smith's Operative Surgery. Surgery of the Upper Gastrointestinal Tract*, 5th edn (eds G. Jamieson and H. Debas), Chapman & Hall, London, 1994, p. 462.]

## *Subtotal gastrectomy*

- Indicated for **carcinoma of pyloric end of stomach**;
- It involves separation of **greater omentum** from colon in its entirety, separation of **lesser omentum** from liver, freeing **subpyloric & celiac axis lymph nodes**, & removing them together with fibrofatty tissue in which they lie.
- Operation is completed by a **Billroth II anastomosis**.
- For a fundal neoplasm, lower third of stomach can be preserved & used for reanastomosis, but spleen & tail of pancreas are included in resection, as well as related lymph nodes.

## ***Palliative operations***

- ***Partial gastrectomy***
  - A Billroth II type is preferred.
- ***Gastrojejunostomy***
  - For irremovable pyloric carcinoma, it should be performed some distance from tumor, so that the advancing growth will not invade stoma for some time.
- ***Traversing plastic tube***
  - For obstruction of cardia.



# Other Treatment Modalities

- **Radiotherapy**
  - For palliative treatment of painful bony metastases.
- **Chemotherapy**
  - Gastric cancer may respond well to combination chemotherapy, eg **epirubicin + cisplatin + 5-fluorouracil**.
  - Intraperitoneal **mitomycin C-impregnated charcoal** has also shown good results

**The End!**