

- A 55-year-old construction worker has smoked 2 packs of cigarettes daily for the past 25 years. He notes swelling in his upper extremity & face, along with dilated veins in this region. What is the most likely cause of the obstruction?

- A. Aortic aneurysm
- B. Metastasis
- C. Bronchogenic carcinoma
- D. Chronic fibrosing mediastinitis
- E. Granulomatous disease

**Answer: C**

# Bronchogenic Carcinoma



**Dr. Muhammad Shamim**  
**Assistant Professor, BMU**

# Introduction

- *Most common malignancy in men & the second most common in women.*
- *There is only a 20% 1-year survival for all cases after diagnosis.*
- *Surgery represents the best chance of prolonged survival.*

# Etiology

- *Cigarette smoking.*
- *Atmospheric pollution.*
- *Certain occupations*
  - *radioactive ore*
  - *chromium mining*

# Pathology

- *Many tumors have more than one cell type.*
- *Behavior and prognosis depend largely on the dominant cell type.*

# Squamous cell carcinoma (60%)

- *Common in smokers.*
- *Tends to be centrally placed.*
- *There is a tendency to cavitate and metastasise outside the thoracic cavity.*

# Adenocarcinoma (15%)

- *More common in females & nonsmokers.*
- *Tends to be sited in the periphery of the lung.*
- *Often metastasise widely to the liver, brain & adrenals.*
- *It is important to exclude secondary adenocarcinoma from other sites such as colon, breast & ovary.*

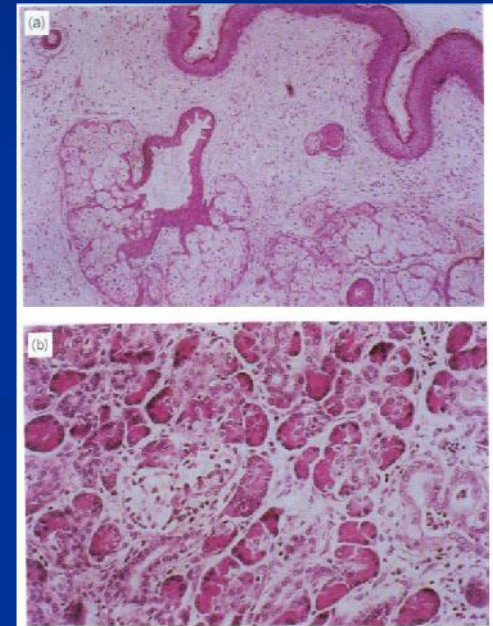


Fig. 47.12 Photomicrograph showing a moderately well-differentiated adenocarcinoma. (Hematoxylin and eosin.)


# Small cell carcinoma

- *Metastasises widely early in its course.*
- *Often associated with ectopic hormone production & paraneoplastic syndromes.*



# Alveolar cell carcinoma

- *Arises in the distal airways.*



■ At the age of 46, an accountant has developed hoarseness due to an inoperable cancer of the left upper lung lobe. He has smoked heavily since the age of 14. Which of the following features of cancer of lung indicates distant spread?

- A. Hypercalcemia
- B. Cushing-like syndrome
- C. Gynecomastia
- D. Syndrome of inappropriate secretion of antidiuretic hormone (SIADH)
- E. Brachial plexus lesion (Pancoast syndrome)

**Answer: E**


# Clinical features

*Primary may causes the followings:*

- *Persistent cough.*
- *Weight loss.*
- *Dyspnea.*
- *Nonspecific chest pain.*
- *Hemoptysis.*
- *Clubbing & hypertrophic pulmonary osteoarthropathy.*

# Features of locally advanced & metastatic disease

- *Severe localized pain.*
- *Pancoast's syndrome.*
- *Hemothorax.*
- *Hoarseness of voice.*
- *Dysphagia.*
- *Superior vena caval obstruction.*
- *Paraneoplastic syndromes.*
- *Hepatomegaly*



■ An asymptomatic 56-year-old man is found on routine chest x-ray to have a 2-cm nodule-central tumor in the upper lobe of the right lung. The lesion is not calcified. What is the most appropriate initial step toward making a diagnosis?

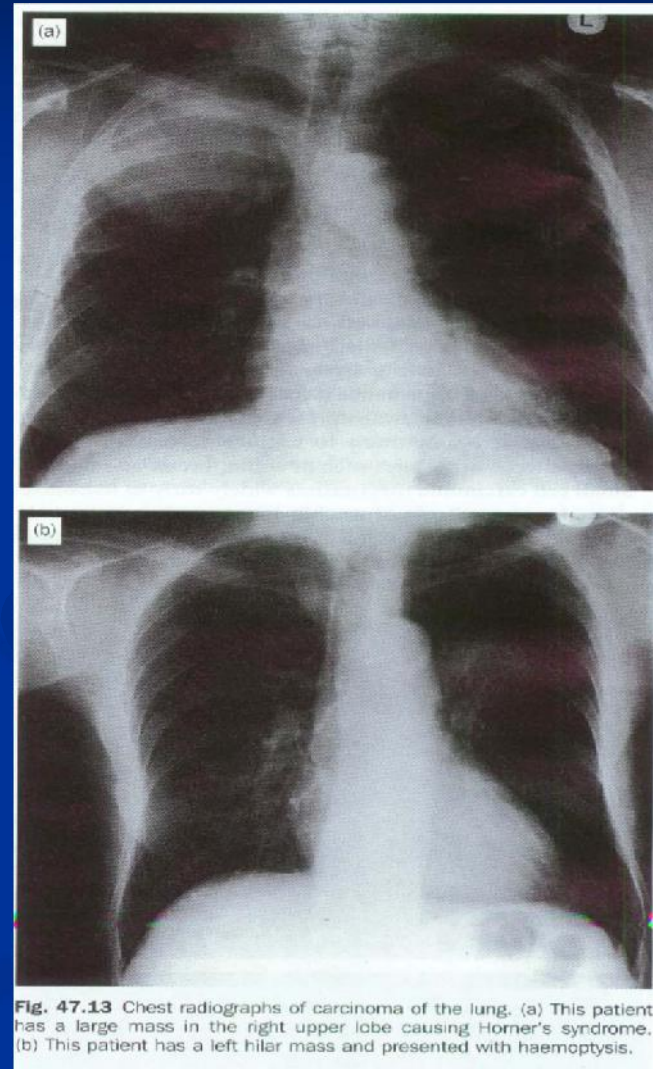
- A. Fiberoptic bronchoscopy
- B. Bone scan
- C. Thoracotomy
- D. Observation at follow-up examination in 6 months
- E. Mediastinoscopy

**Answer: A**

# Diagnostic investigations

- *Chest radiography*

Pleural effusion, lobar collapse, raised hemidiaphragm.



- *Computerised tomography (CT)*

Shows the tumor & its extensions, mediastinal lymph nodes, & hepatic metastasis.

- *Sputum cytology*

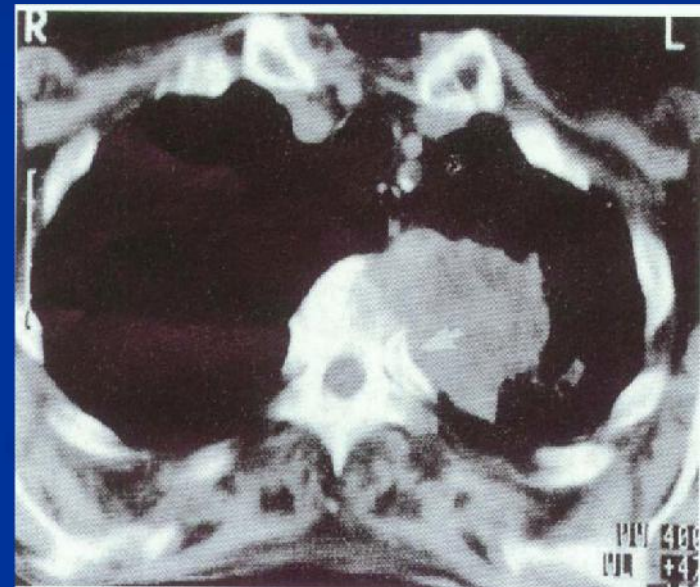

Fig. 47.14 Computerised tomogram of the upper thorax showing a Pancoast tumour invading the adjacent vertebra, making the tumour inoperable.

# Bronchoscopy

- *Flexible or rigid bronchoscopy.*
- *Biopsy is hazardous in:*
  - **bleeding disorders**
  - **systemic anticoagulation**
  - **pulmonary hypertension**
- *Complications include*
  - *Bleeding*
  - *Pneumothorax*
  - *Laryngospasm*
  - *arrhythmia.*

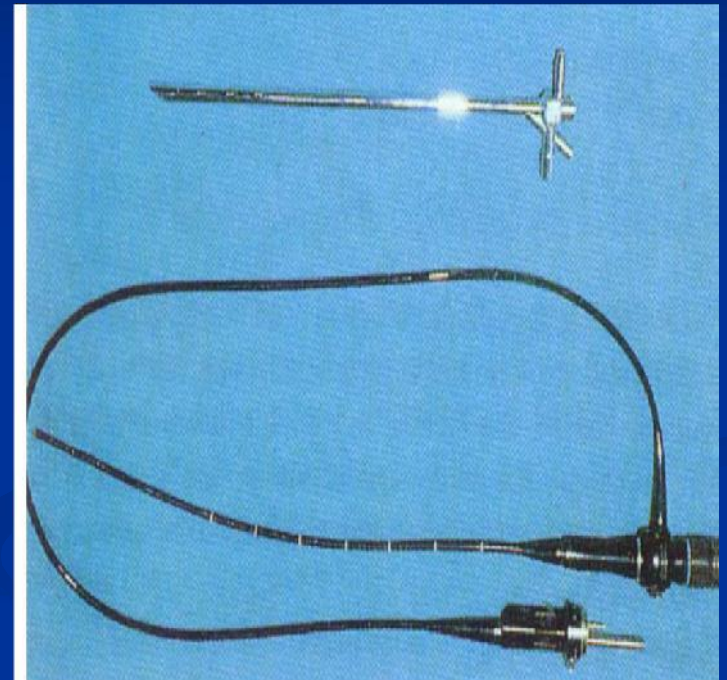
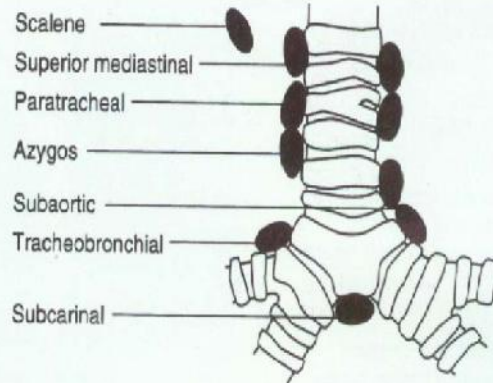


Fig. 47.15 Rigid and flexible rigid bronchoscope.

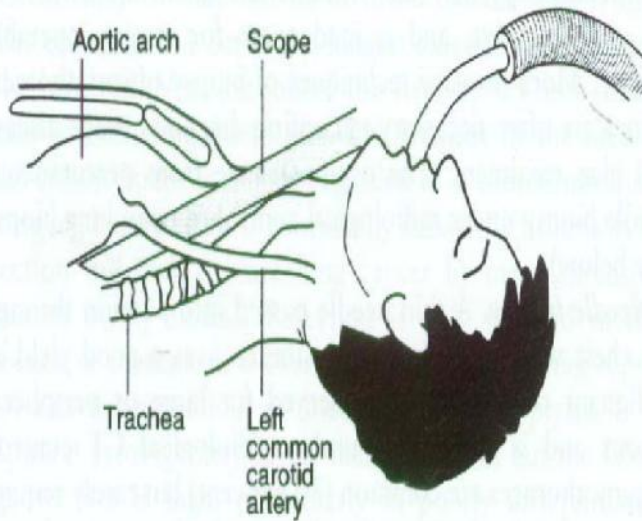


## Other biopsy techniques

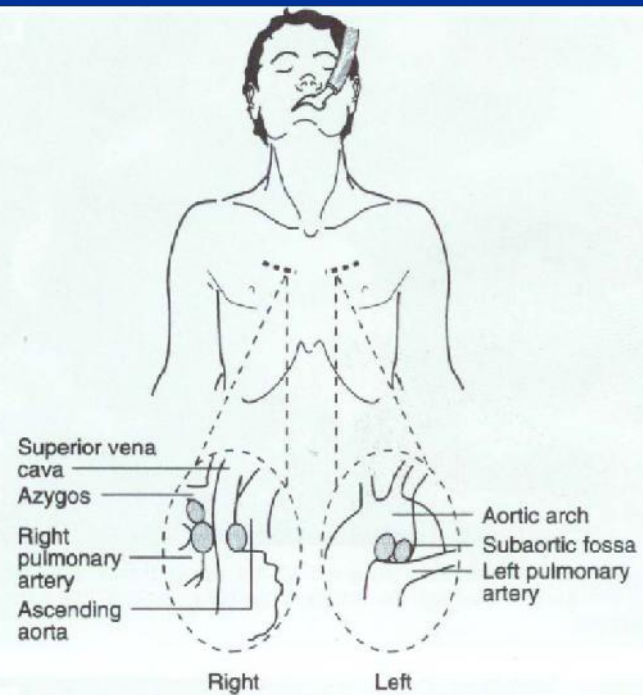
- *Percutaneous needle biopsy under radiological control.*
- *Mediastinoscopy or mediastinotomy*
  - **Advisable on all patients who have enlarged mediastinal lymph nodes (>1 cm) on CT.**
- *Thoracoscopy & biopsy*
- *Open lung biopsy*



**Fig. 47.18** Lymph node sites accessible by the techniques of mediastinotomy and mediastinoscopy.



**Fig. 47.16** Diagram of mediastinoscopy. The mediastinoscope slides down immediately in front of the trachea behind the aortic arch and behind and between the great vessels of the head and neck.



**Fig. 47.17** Diagram of mediastinotomy. Structures accessible through anterior mediastinotomy.

# TNM staging

## Primary tumor (T)

- **TX** Tumor proven by cytology but not visualized.
- **T0** No evidence of primary tumor
- **Tis** Carcinoma in situ
- **T1** Tumor upto 3 cm, within visceral pleura & distal to lobar bronchus.
- **T2** Tumor >3 cm or invading visceral pleura, or within lobar bronchus but 2 cm distal to carina.
- **T3** Any size, with extension to chest wall, or within main bronchus within 2 cm of carina.
- **T4** Any size, involving mediastinum or its contents, vertebral body or carina or malignant pleural effusion.

## Nodes (N)

- N0
- N1 Peribronchial or ipsilateral hilar nodes, or both.
- N2 Ipsilateral mediastinal & subcarinal nodes.
- N3 Contralateral mediastinal or hilar, ipsilateral or contralateral scalene or supraclavicular nodes.

## Distant metastasis (M)

- M0
- M1

■ After undergoing a percutaneous needle biopsy, a 49-year-old electrical engineer is found to have small cell carcinoma. Chest x-ray shows a lesion in the peripheral part of the right middle lobe. The patient should be advised to undergo which of the following?

- A. Right lobectomy
- B. Right pneumonectomy
- C. Excision of lesion & postoperative radiotherapy
- D. Combination chemotherapy
- E. Radiotherapy

**Answer: D**

# Treatment

- *Tumours graded  $T_2$ ,  $N_1$ ,  $M_0$  or less have a better prognosis when treated surgically.*

**Table 47.4** Staging of carcinoma of the lung

Stage	Tumour	Nodal involvement	Distant metastasis	
Occult carcinoma	TX	$N_0$	$M_0$	} Operable
Stage 0	TIS			
Stage I	$T_1$	$N_0$	$M_0$	
Stage II	$T_1$ $T_2$	$N_1$ $N_1$	$M_0$ $M_0$	
Stage IIIa	$T_3$	$N_0$	$M_0$	} Inoperable
	$T_3$	$N_1$	$M_0$	
Stage IIIb	$T_{1-3}$ Any T	$N_2$ $N_3$	$M_0$ $M_0$	
Stage IV	$T_4$ Any T	Any N Any N	$M_0$ $M_1$	

# Surgical management

*Principle of surgery is to remove all cancer (the primary and the regional lymph nodes) but to conserve as much lung as possible:*

1. *Lobectomy*
2. *Segmentectomy or simple wedge excision.*
3. *Pneumonectomy.*
  - **This procedure is reserved for either centrally placed tumours involving the main bronchus or those that straddle the fissure.**

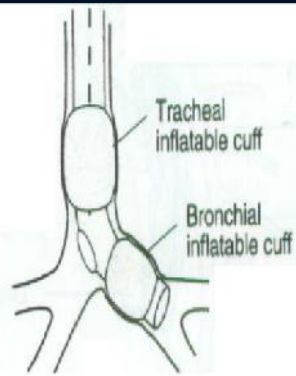
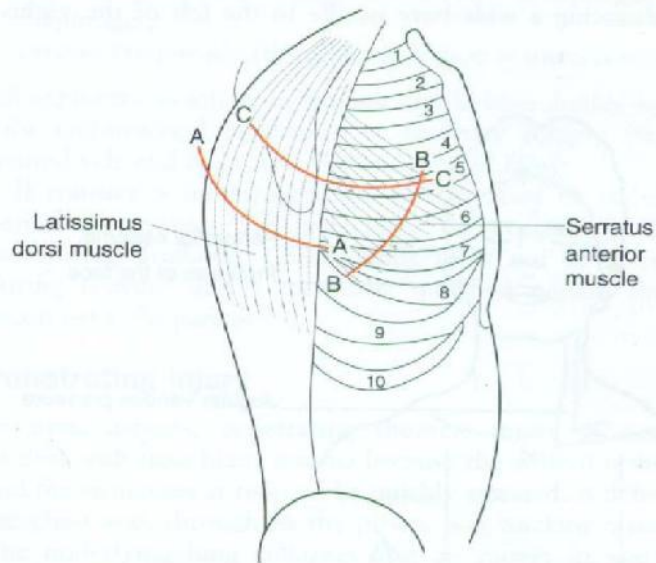


Fig. 47.19 The theory behind single lung anaesthesia.



- A- A The latissimus dorsi is divided in line with the skin incision
- B- B The serratus anterior is divided close to its attachment to ribs 6, 7 and 8
- C- C The intercostal muscles are stripped off the upper border of the rib

Fig. 47.10 Diagram of incision and layers encountered during anterolateral thoracotomy.

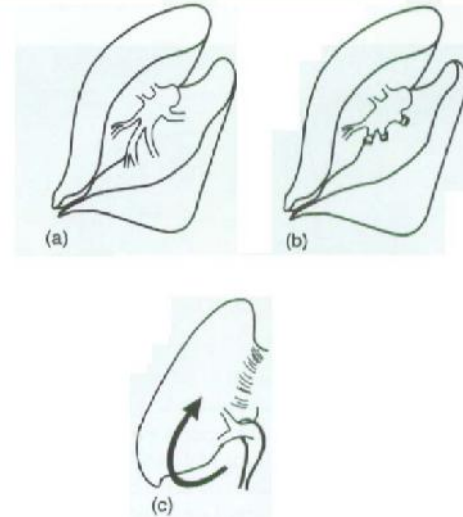


Fig. 47.20 Diagram of stages in lobectomy. (a) Pulmonary branches in fissure; (b) apical lower and basal divided, upper and lingula conserved; (c) inferior vein found inferiorly by turning lung up.

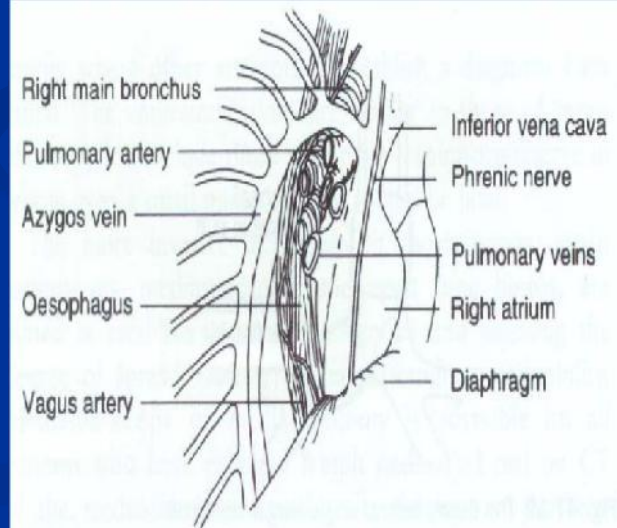


Fig. 47.21 Mediastinal structures after removal of right lung.



## ■ Thoracoscopic lung resection

- Lung biopsy & treatment of recurrent pneumothorax are the most frequent indications.
- Pneumonectomy, lobectomy & empyema drainage are all possible.

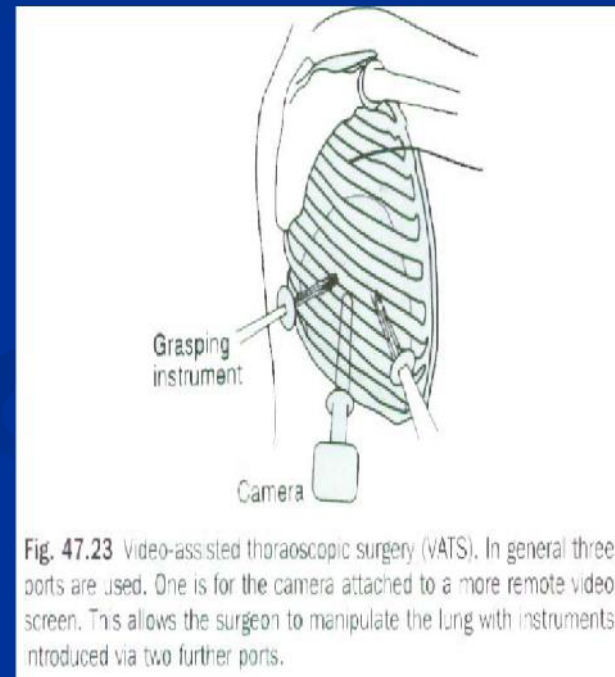


Fig. 47.23 Video-assisted thoracoscopic surgery (VATS). In general three ports are used. One is for the camera attached to a more remote video screen. This allows the surgeon to manipulate the lung with instruments introduced via two further ports.

# Complications of lung resection

- *Bleeding.*
- *Respiratory infection.*
- *Persistent air leak.*
- *Bronchopleural fistula.*
- *Hypoxaemia.*

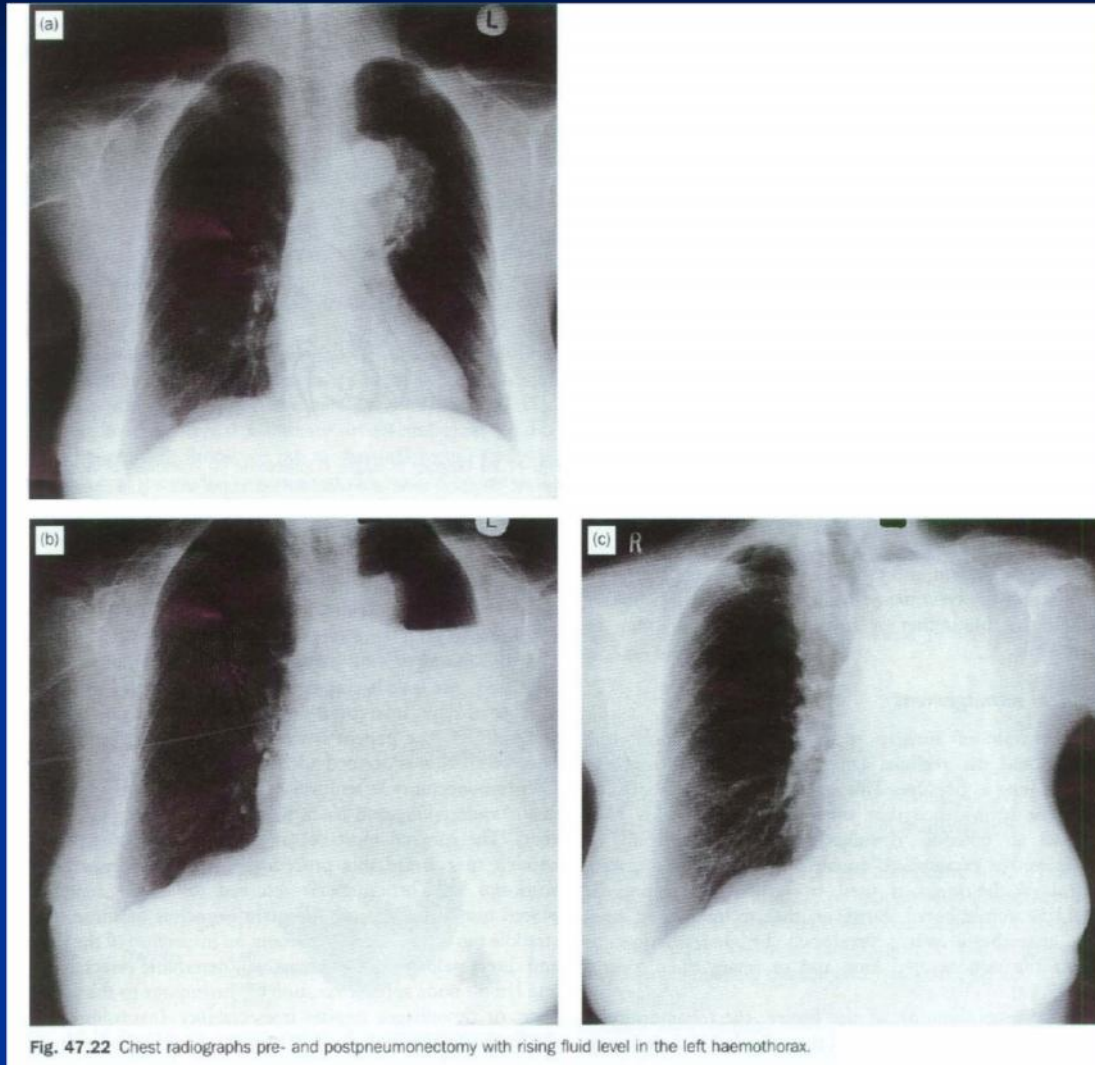


Fig. 47.22 Chest radiographs pre- and postpneumonectomy with rising fluid level in the left haemothorax.

# Other treatment modality

- *Radiotherapy*
- *Chemotherapy*

# Survival

- *The 5-year survival rate is less than 2%*
  - *if no treatment is offered at the time of diagnosis and ipsilateral lymph nodes are involved.*
- *15-30% 5-year survival*
  - *Those with mediastinal lymph nodes discovered and removed at thoracotomy.*

**Table 47.5** Survival table for carcinoma of the bronchus

<i>Five-year survival according to presurgical staging</i>	<i>%</i>
Stage I	56-67
Stage II	39-55
Stage IIIa	23
Stage IIIb	<10

<i>Five-year survival according to cell type</i>	<i>%</i>
Squamous cell carcinoma	35-50
Adenocarcinoma	25-45
Adenosquamous carcinoma	20-35
Undifferentiated carcinoma	15-25
Small cell carcinoma	0-5

**Thank you!**